

## CASE REPORT

# Heterotopic Pregnancy in a Natural Conception

Sumeet N Baheti, K Jayakrishnan

KJK Hospital, Nalanchira, Trivandrum, Kerala, India

**Correspondence:** K Jayakrishnan, KJK Hospital, Shawallace Lane, Nalanchira, Trivandrum-695015, Kerala, India  
Phone: 91-471-2544080, e-mail: kjkhospital@gmail.com

## ABSTRACT

Heterotopic pregnancy is rare in natural conception and most often presents as life threatening emergency like acute abdomen and hemorrhagic shock. In early unruptured stages, it presents nonspecifically, mimicking normal or abnormal pregnancy manifestations. A high index of suspicion and a definitive search for it even after confirming normal intrauterine gestation is needed. This little effort ensures a timely diagnosis and management thus preventing catastrophe. We hereby report a primigravida with unruptured heterotopic pregnancy following a natural conception, who presented as nonspecific abdominal pain. Transvaginal ultrasound was inconclusive. Emergency laparoscopy clinched the diagnosis and allowed conservative salpingostomy and continuation of intrauterine pregnancy.

**Keywords:** Heterotopic pregnancy, Ectopic pregnancy, Natural conception, Transvaginal ultrasonography.

## INTRODUCTION

A heterotopic pregnancy is multiple pregnancies with one or more intrauterine pregnancies coexisting with an ectopic one. Heterotopic pregnancy in natural conception is rare. Early in the course, it presents nonspecifically and is often confused with other normal or abnormal pregnancy manifestations.<sup>1</sup> Although advancement in ultrasound technology can aid in diagnosis, the demonstration of a viable intrauterine pregnancy is often taken as exclusion of ectopic pregnancy. This practice delays diagnosis of heterotopic pregnancy leading to significant morbidity and mortality.<sup>1</sup> We describe a case report of unruptured heterotopic pregnancy following natural conception, presenting with nonspecific abdominal pain. A high index of suspicion ensured timely diagnosis and management with continuation of normal intrauterine gestation.

## CASE REPORT

A 24 years old primigravida, spontaneous conception with 6 weeks gestation was referred to our center with history of dark reddish-brown vaginal discharge and intermittent dull lower-quadrant discomfort of one week duration. She had no prior history of pelvic inflammatory disease (PID) or fertility treatments. On admission her vitals were stable. Pelvic examination showed that she had an enlarged uterus corresponding to 6 to 8 weeks of pregnancy with a closed cervix and a tender right adnexum. Her hemoglobin concentration was 8.4 gm/dL. Serum b-hCG concentration was 90000 mIU/mL. Repeat hemoglobin concentration was 7.4 gm%. Transvaginal

ultrasonography showed single live intrauterine gestation corresponding to 6 weeks and 3 days according to crown-rump length. The left adnexa was unremarkable, but the right adnexa showed inhomogeneous hyperechoic mass  $5.3 \times 4.8$  cm (Fig. 1). The right ovary was not identified separately. Free fluid with echogenic particles suggesting hemoperitoneum was seen.

A differential diagnosis of ruptured right ovarian hemorrhagic cyst or a coexistent ectopic pregnancy with associated hemoperitoneum was made and patient was posted for laparoscopy.

Laparoscopy showed that the patient had an unruptured ectopic pregnancy in the ampullary part of the right tube (Fig. 2) and approximately 200 mL of blood in the peritoneal cavity. Left fallopian tube and bilateral ovaries were normal. A conservative salpingostomy with evacuation of the intratubal conceptus was performed. The patient had an uneventful postoperative course, follow-up after 4 weeks confirmed the viability of the ongoing intrauterine pregnancy (Fig. 3). The histopathology report confirmed a tubal ectopic pregnancy.

## DISCUSSION

Heterotopic pregnancy, once thought to be an extremely rare phenomenon, is becoming more common and occurs in various forms, such as bilateral or unilateral tubal, abdominal, cervical and ovarian pregnancy.<sup>2,3</sup> The most frequent form is tubal heterotopic pregnancy. There are many risk factors for heterotopic pregnancy, such as previous tubal damage (after PID, endometriosis or previous tubal surgery), ectopic pregnancy, and assisted reproductive techniques (pharmacologic ovulation stimulation, *in vitro* fertilization, gamete intrafallopian transfer).<sup>1,2,4</sup> Also, a few cases have been reported in natural cycles.<sup>5</sup>

Date of Received: 28-08-10

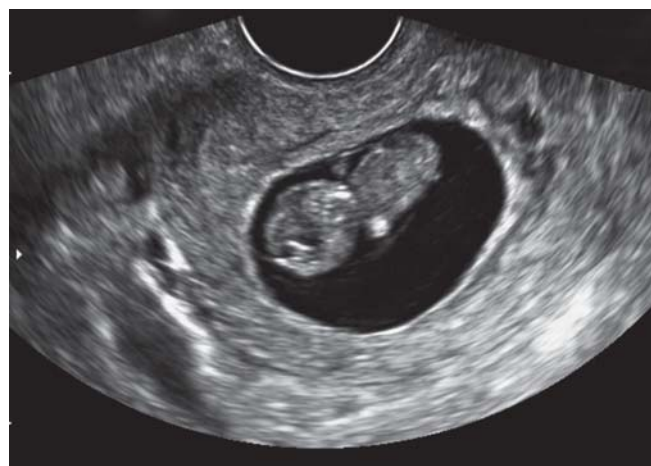Date of Acceptance: 25-09-10

Date of Publication: Sep. 2010

Historically, the incidence was estimated as one in 30,000 in spontaneous pregnancies, but a more recent re-evaluation of the incidence of heterotopic pregnancy in the general population presents a fairly conservative estimate as one in every 7000 pregnancies.<sup>3,6</sup> However, with assisted reproduction techniques, this incidence increases to 1 in 100.<sup>1</sup>

The clinical presentation of unruptured heterotopic pregnancy is variable and highly nonspecific. The common presenting signs and symptoms are abdominal pain, adnexal mass, peritoneal irritation, and an enlarged uterus.<sup>7</sup> Heterotopic pregnancy is most likely to be missed in natural conception, unless the sonologist is aware of and carefully screens the tubes and pelvis. If overlooked, it may present with rupture and acute abdominal syndrome, which can lead to maternal shock or death.

Transvaginal ultrasonography is an important aid in the diagnosis of heterotopic pregnancy, but ultrasonographic identification of ectopic pregnancy is low in its sensitivity.<sup>8</sup> Some findings, such as extrauterine gestational sac with fetal cardiac activity, fetal node, and hyperechoic ring surrounding the gestational sac and adnexal mass, point to tubal heterotopic pregnancy. Suspicious adnexal masses can be investigated with Doppler ultrasound in an attempt to improve sensitivity and specificity. Taylor and coworkers have described



**Fig. 3:** Transvaginal ultrasonography showing ongoing viable intrauterine pregnancy

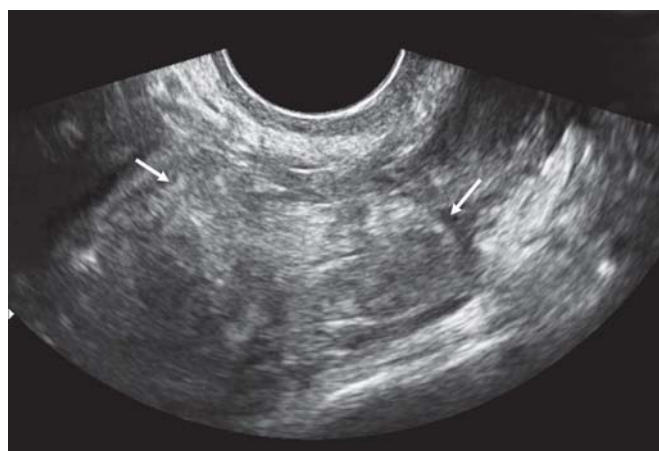a high velocity, low resistance Doppler signal that is associated with the developing trophoblast. They report that identification of this type of flow pattern in an adnexal mass using transvaginal color Doppler has a sensitivity of 96% and a specificity of 93%.<sup>9</sup> In other cases, it may be difficult to differentiate an ectopic pregnancy from a hemorrhagic corpus luteum cyst. Presence of moderate or large amounts of intraperitoneal bleed should obviously raise suspicion of ectopic pregnancy.<sup>10</sup> The difficulty of an accurate clinical and sonographic diagnosis in symptomatic patients can, per se, justify a laparoscopy as in our cases.

There are three options for the management of heterotopic pregnancy. First, some cases can resolve spontaneously.<sup>11</sup> These cases can be followed without any intervention. However, there are no clear guidelines or tests showing, which patients can be followed. Also, monitoring human chorionic gonadotropin level or sonographic assessment is not helpful. The second option is medical treatment. Potassium chloride or hyper osmolar glucose can be injected locally into the intact heterotopic gestational sac or fetus via laparoscopy or transvaginal sonography.<sup>4</sup> Other drugs used in the medical treatment of ectopic pregnancy, such as methotrexate, RU486 and prostaglandins, cannot be used because of the possibility of harmful effects on an intrauterine pregnancy.<sup>4</sup> These two options are useful in very few cases.

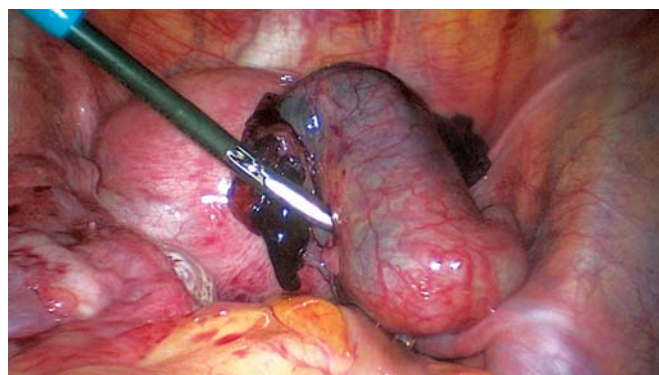
The last option is surgical removal of the ectopic gestation by salpingectomy or salpingostomy. Laparotomy was used widely in the past, but laparoscopy is now preferred due to early postsurgical recovery.<sup>12</sup> However, laparotomy may be the preferable surgical modality in cases with serious intra-abdominal bleeding or in patients with hemorrhagic shock. Removal of ectopic implantation with minimal trauma and avoidance of intraperitoneal hemorrhage improves the survival of an intrauterine pregnancy with favorable outcome reported in 50 to 66% cases.<sup>1</sup>

## CONCLUSION

Heterotopic pregnancy should be kept in mind even if an intrauterine pregnancy is diagnosed and one should take extra



**Fig. 1:** Transvaginal ultrasonography showing inhomogeneous hyperechoic mass (white arrows) in the right adnexa



**Fig. 2:** Laparoscopy showing unruptured ectopic pregnancy in the ampullary part of the right tube

efforts to look for the same. This high index of suspicion is to ensure a timely diagnosis and management, so as to prevent catastrophe like tubal rupture and hemorrhagic shock which can be life-threatening.

## REFERENCES

1. Tal J, Haddad S, Gordon N, Timor-Tritsch I. Heterotopic pregnancy after ovulation induction and assisted reproductive technologies: A literature review from 1971 to 1993. *Fertil Steril* 1996;66:1-12.
2. Marcus SF, Macnamee M, Brinsden P. Heterotopic pregnancies after in vitro fertilization and embryo transfer. *Hum. Reprod.* 1995;10:1232-36.
3. Devoe R, Pratt J. Simultaneous intrauterine and extrauterine pregnancies. *Am J Obstet Gynecol* 1948;56:1119-26.
4. Scheiber MD, Cedars MI. Successful non-surgical management of a heterotopic abdominal pregnancy following embryo transfer with cryopreserve-thawed embryos. *Hum Reprod* 1999;14:1375-77.
5. Jerrard D, Tso E, Salik R, Barish RA. Unsuspected heterotopic pregnancy in a woman without risk factors. *Am J Emerg Med* 1992;10:58-60.
6. Richards SR, Stempel LE, Carlton BD. Heterotopic pregnancy: Reappraisal of incidence. *Am J Obst Gynecol* 1982;142(7):928-30.
7. Reece EA, Petrie RH, Sirmans MF, Finster M, Todd WD. Combined intrauterine and extrauterine gestations: A review. *Am J Obstet Gynecol* 1983;146:323-30.
8. Ankum WM, Vander Veen F, Hamerlynck JV, Lammes FB. Transvaginal sonography and human chorionic gonadotrophin measurements in suspected ectopic pregnancy: A detailed analysis of a diagnostic approach. *Hum Reprod* 1993;8:1307-11.
9. Taylor KJ, Ramos IM, Feyock AL, Snower DP, Carter D, Shapiro BS, et al. Ectopic pregnancy: Duplex Doppler evaluation. *Radiology* 1989;173:93-97.
10. Romero R, Kadar N, Castro D. The value of adnexal sonographic findings in the diagnosis of ectopic pregnancy. *Am. J. Obstet. Gynecol* 1988;158:52-55.
11. Wang YL, Yang TS, Chang SP, Ng HT. Heterotopic pregnancy after GIFT managed with expectancy: A case report. *Zhonghua Yi Xue Za Zhi (Taipei)* 1996;58:218-22.
12. Pschera H, Kandemir S. Laparoscopic treatment of heterotopic pregnancies: Benefits, complications and safety aspects. *J Turkish German Gynecol Assoc* 2005;6:90-94.